

See discussions, stats, and author profiles for this publication at: <https://www.researchgate.net/publication/361163018>

# Comparison and Evaluation of the Combine Alcian Blue –PAS and Hematoxylin and Eosin in the Detection of Gastric Intestinal Metaplasia among Sudanese Patients with Chronic Gastritis

Article · June 2022

DOI: 10.47363/JCRR/2022(4)161

CITATIONS

0

READS

75

5 authors, including:



**Ghanem Mohammed Mahjaf**

Shendi University

72 PUBLICATIONS 3 CITATIONS

SEE PROFILE



**Mosab Nouraldein Mohammed Hamad**

Elsheikh Abdallah Elbadri University

566 PUBLICATIONS 171 CITATIONS

SEE PROFILE



**Lana Jamal Abubaker**

Sudan University of Science and Technology

10 PUBLICATIONS 7 CITATIONS

SEE PROFILE

## Research Article

## Open Access

## Comparison and Evaluation of the Combine Alcian Blue -PAS and Hematoxylin and Eosin in the Detection of Gastric Intestinal Metaplasia among Sudanese Patients with Chronic Gastritis

Abd Alrhmman Ali Alkalifa Alhafyan<sup>1</sup>, Ibrahim B Elemam<sup>1</sup>, Zeinab A Mohamed<sup>1</sup>, Ghanem Mohammed Mahjaf<sup>2</sup>, Lana Jamal Abubaker<sup>2</sup> and Mosab Nouraldein Mohammed Hamad<sup>3\*</sup>

<sup>1</sup>Department of Histopathology & Cytology, College of Medical Laboratory Science, Shendi University, Shendi, Sudan

<sup>2</sup>Department of Medical Microbiology, College of Medical Laboratory Sciences, Shendi University, Shendi, Sudan

<sup>3</sup>Head of Parasitology Department, College of Health and Allied Sciences, St. Joseph University In Tanzania, Dar Es Salaam, Tanzania

### ABSTRACT

Gastric cancer is the fifth most common cancer and the second most frequent cause of cancer death worldwide, gastric cancer remains a major cause of mortality and morbidity worldwide. Gastric intestinal metaplasia, an intermediate step in gastric carcinogenesis, is generally regarded as a pre-malignant lesion. Gastric intestinal metaplasia is a precancerous modification of the mucosa of the stomach with intestinal epithelium and is associated with an expanded danger of dysplasia and cancer. The study aimed to compare and evaluate the combined alcian blue -PAS and Hematoxylin and Eosin, in the detection of gastric intestinal metaplasia among Sudanese patients with chronic gastritis. Two hundred tissue sections were cut from 100 formalin-fixed paraffin-embedded Blocks (n=100) were collected from patients who attended El-mek Nimir University Hospital & Specialized Centers at Shendi locality- River Nile State between June to December 2021, and thereafter processed and examined histopathologically, all blocks were cut into (3 micrometers) by using SLEE-MAINZ,-CUT4060 microtome. And spread in a water bath then put in coated glass slides, then all sections deparaffinized in xylene and rehydrated through descending grade of alcohols, then water. 100 tissue sections were stained by hematoxylin and eosin technique and 100 were stained by combined alcian blue -PAS stain technique. Combine Alcian blue & PAS is more detected the Gastric Intestinal Metaplasia compared to H& E was observed among chronic gastritis patients in Combine Alcian blue & PAS technique positive in 19 (19%) cases and negative in 81 (81%), by routine H& E is positive in 11 (11%), cases and negative in 89 (89%) cases and the overall prevalence of gastric intestinal Metaplasia was 19%, from which 12 (63.1%) among female, and 7 (36.8%) were male and the age they classify into three groups A (10-40 years) group B (41-70 years) group C (71-100 years) the result of GIM positive rate was found 2 (6.6%), 10 (23.3%), 7 (25.9%) respectively. On the other hand, the sensitivity of H& E in the detection of (GIM) was 70.3% and specificity was 100%. The study concluded that combining Alcian blue & PAS is more detected and sensitive in the detection of gastric intestinal metaplasia among Sudanese Patients with chronic gastritis compared to H& E. Additionally, The most positive rate was among females and within the age group (41-70) years old was observed. This may direct the clinicians and researchers to it could be better to use combined Alcian blue & PAS in diagnosing Gastric Intestinal Metaplasia and look for more information about the detection of gastric intestinal metaplasia.

### \*Corresponding author

Mosab Nouraldein Mohammed Hamad, Head of Parasitology Department, College of Health and Allied Sciences, St. Joseph University in Tanzania, Dar Es Salaam, Tanzania. E-mail: musab.noor13@gmail.com

**Received:** May 30, 2022; **Accepted:** June 07, 2022; **Published:** June 14, 2022

**Keywords:** Gastric Cancer, Gastric Intestinal Metaplasia, Alcian Blue, PAS and Hematoxylin and Eosin, Chronic Gastritis Patients, Shendi, Sudan

### Introduction

Gastric cancer is the fifth most common cancer and the second most frequent cause of cancer death worldwide [1]. Gastric cancer remains a major cause of mortality and morbidity worldwide, and the total number of gastric cancer cases, contributing to more than 1 million cases per year and 5.7% of all cancer diagnoses, is predicted to rise as a result of population growth. Historically gastric adenocarcinomas were subdivided by the Laurén histological classification into intestinal and diffuse subtypes. The intestinal type appears to arise from a background of chronic atrophic gastritis,

with the development of intestinal metaplasia and transition through progressively increasing stages of dysplasia to carcinoma [2]. Metaplasia is the replacement of one differentiated cell type with another mature differentiated cell type that is not normally present in a specific tissue IM in the stomach is histologically described as modifications in gland structure (to resemble intestinal glands) and the presence of intestine-specific lineage cells that are not currently in the typical stomach such as goblet cells and Paneth cells [3]. Intestinal metaplasia in the stomach expansions the possibility of intestinal cancer, and the expanded danger is proportionate to the dimensions of the metaplasia. This risk could be generated by one or more devices, the metaplastic tissue is an early step in a multistep induction process; the metaplastic tissue is an epigenetic change that raises the pH of gastric juice by replacing oxyntic mucosa, favoring

the growth of a bacteria capable of generating endogenous mutagens; and/or the metaplasia is only a marker for chronic gastritis due to H. pylori infection or pernicious anemia. With the last mechanism, the inflammatory response favors intramural mutagenesis that might result in metaplasia or neoplasia as independent events [4]. Gastric intestinal metaplasia (GIM) is readily seen in Hematoxylin and eosin-stained slides of gastric biopsies, The diagnosis of GIM can be made when one or more definite goblet cells are identified in the routine Hematoxylin and eosin stain, many pathology laboratories perform routine special stains on all of these biopsies, the presence and extent of intestinal metaplasia can also be evaluated with the use of specific mucin histochemical stains. For instance, the Alcian blue/periodic acid–Schiff (AB/PAS) stain at pH 2.5 is an excellent method to demonstrate the type and extent of intestinal metaplasia, particularly when used in combination with a hematoxylin counterstain. Mucin histochemical stains were traditionally used to determine intestinal metaplasia by detecting sulfated mucin [5].

**Materials and Methods**

A hundred formalin-fixed paraffin-embedded Blocks (n=100) were collected from patients who attended El-mek Nimir University Hospital & Specialized Centers in Shendi locality with different ages (12-97 years) and were diagnosed previously with chronic gastritis, during a period from June to December 2021 were included in this study after being given their informed consent. Two hundred tissue sections cutting from 100 formalin fixed paraffin-embedded Blocks. All blocks are cut into (3micrometer) by using SLEE-MAINZ,-CUT4060microtome, and spread in a water bath then put in coated glass slides, then all sections deparaffinized in xylene and rehydrated through descending grade of alcohols, then water. Then 100 sections were stained by the combined Alcian blue & PAS and 100 sections were stained by H& E.

**Results**

Two hundred tissue sections were examined histopathologically and assessed for the presence of gastric intestinal metaplasia. The Histopathological examination revealed that the detection of GIM by routine H&E is positive in 11 (11%), cases and negative in 89 (89%) cases, and combine alcian blue & PAS technique positive in 19 (19%) cases and negative in 81 (81%) (Table 1). Our study illustrated that the overall prevalence of gastric intestinal Metaplasia among chronic gastritis was 19%, a female predominance, with the prevalence of 6 (9.8%) females compared to 5 (12.8%) in males in H&E, 12 (19.6%) female compared to 7 (17.9%) in males in combination alcian blue & PAS (Table 2). The age they classify into three groups A (10-40 years) group B (41-70 years) group C (71-100 years) the result of GIM positive rate in H& E was found 2(6.6%), 4 (9.3%), 5 (18.5%) respectively and in combine alcian blue & PAS was found 2 (6.6), 10 (23.3%), 7 (25.9%) respectively (Table 3). The sensitivity and specificity of H& E by using a combination of alcian blue & PAS technique as the reference method, was found that Sensitivity (70.3%) and Specificity (100%) Sensitivity = True positive ÷ True positive + False negative × 100=27×100=70.3%), Specificity = True Negative ÷ True Negative + False positive × 100 (81÷81×100=100%) (Table 4).

**Table 1: Show Prevalence of Gastric Intestinal Metaplasia by H& E and Combine Alcian Blue & PAS Technique**

Techniques	Positive	Negative	Total
H& E	11	89	100
Combination Alcian Blue & PAS	19	81	

**Table 2: Prevalence of Gastric Intestinal Metaplasia among the Gender**

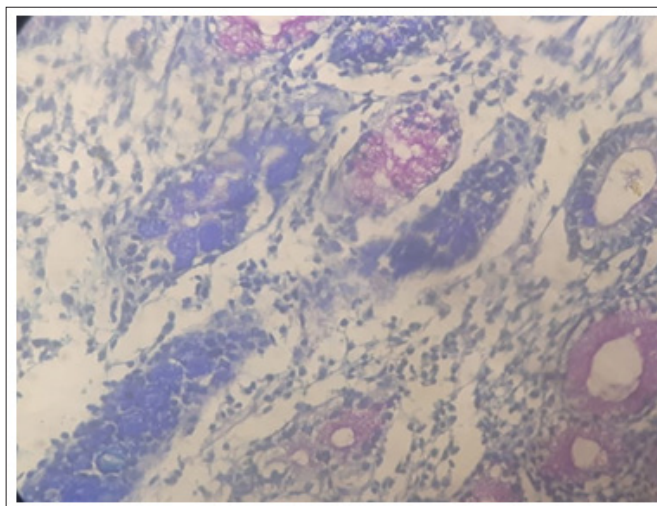
Sex	H& E	Combination Alcian Blue & PAS
Male	5 (12.8%)	7 (17.9%)
Female	6 (9.8%)	12 (19.6%)
Total	19	81

**Table 3: Show Compare between Age Group and H& E and Combine Alcian Blue & PAS Result in Gastric Intestinal Metaplasia**

Sex	H& E	Combination Alcian Blue & PAS
10-40 years	2 (6.6%)	2 (6.6)
41-70 years	4 (9.3%)	10 (23.3%)
71-100 years	5 (18.5%)	7 (25.9%)
Total	11	19

**Table 4: Sensitivity and Specificity of H& E by using Combination Alcian Blue & PAS Technique as Reference Method**

Techniques	Positive	Negative	Total
Combination Alcian Blue & PAS	19	81	100
H&E	11	89	



**Figure 1: Slide Section Stained by Combine Alcian Blue & PAS Technique, of 54 Years Old Patient with Chronic Gastritis and Presence of Positive Acid and Neutral Mucin Indicate that Gastric Intestinal Metaplasia**

**Discussion**

Our Finding shows that the detection of (GIM) by Routine H&E is positive in 11 (11%), cases and negative in 89 (89%) cases. In combined Alcian blue & PAS technique was positive in 19 (19%) cases and negative in 81 (81%) these findings were in agreement with the study done by Mandal PK, Chakrabarti S, et al, in 2013, was studied the mucin histochemistry of the stomach in metaplasia. GIM was found in 9 (12.9%) cases by Hematoxylin and eosin, Where showed periodic acid Schiff-alcian blue (PAS-AB) positive staining in 15 (21.4%) cases [6]. our findings were in agreement with the study conducted by Byrne JP, Bhatnagar, and his colleges, in 1999, they reveal that the intestinal metaplasia was 9 (4.6%) detected by H& E while the acid mucin stains were positive in 75 (38.7%) [7]. Also, our study illustrated that the

overall prevalence of gastric intestinal Metaplasia among chronic gastritis was 19%, a female predominance, with the prevalence of 12 (19.6%) compared to 7 (17.9%) in males., this result agrees with the study conducted in the United States by Tarek Almouradi and his team [8]. This may be explained by fact that women seek more health care compared to males. Our Findings reveal that a higher positive rate of (GIM) was found in age between (41-70) years old representing (43%) of the overall age group, that support that GIM has significantly increased with advanced age this result agrees with the study done by Mandal PK, Chakrabarti S, et al, in 2013, that found in a total of 26 patients (37.1%) of were found in 41-50 years age group followed by 19 (27.1%) in the 51-60 years and 9 (12.9%) in 61-70 years group [6]. Our study also assesses the sensitivity and specificity of H&E compared with the combination Alcian Blue & PAS technique as the reference method, the sensitivity of H& E (70.3 %) and the specificity (100%), this result agreement with the study done in Saudi Arabia done by Alkhamiss AS, in 2013, their result that the sensitivity of H&E (66.6 %) and specificity (100%) [9]. Our Findings prove that gastric intestinal metaplasia is better to be detected by combining Alcian blue & PAS techniques.

### Conclusion

In this study, we concluded that combining alcian blue & PAS is more detected the gastric intestinal metaplasia compared to H&E the prevalence of gastric intestinal metaplasia among chronic gastritis was 19%. The most positive rate were females and within the age group (41-70) years old. The combined alcian blue & PAS is more sensitive to detect (GIM) compared to H&E.

### Conflict of Interests

The authors have not declared any conflict of interest.

### Acknowledgement

The authors appreciate the ethical review committee, thanks are also due to the department of histopathology & cytology at the faculty of medical laboratory sciences and El-mek Nimir University Hospital & Specialized Centers in Shendi locality.

### Funding

There was no specific grant for this research from any funding agencies.

### References

1. Catalano V, Labianca R, Beretta GD, Gatta G, De Braud F, et al. (2009) Critical reviews in oncology/hematology. Gastric cancer 71: 127-164.
2. Lochhead P, El-Omar EM (2008) British medical bulletin. Gastric cancer 85: 87-100.
3. Kinoshita H, Hayakawa Y, Koike K (2017) Metaplasia in the stomach-precursor of gastric cancer? International journal of molecular sciences 18: 2063.
4. Stemmermann GN (1994) Intestinal metaplasia of the stomach. A status report. Cancer 74: 556-564.
5. Zullo A, Hassan C, Romiti A, Giusto M, Guerriero C, et al. (2012) Follow-up of intestinal metaplasia in the stomach: When, how and why. World journal of gastrointestinal oncology 4: 30.
6. Mandal PK, Chakrabarti S, Ray A, Chattopadhyay B, Das S (2013) Mucin histochemistry of stomach in metaplasia and adenocarcinoma: An observation. Indian journal of medical and paediatric oncology: official journal of Indian Society of Medical & Paediatric Oncology 34: 229.
7. Byrne JP, Bhatnagar S, Hamid B, Armstrong GR, Attwood SE (1999) Comparative study of intestinal metaplasia and mucin staining at the cardia and esophagogastric junction in 225 symptomatic patients presenting for diagnostic open-access gastroscopy. The American journal of gastroenterology 94: 98-103.
8. Almouradi T, Hiatt T, Attar B (2013) Gastric intestinal metaplasia in an underserved population in the USA: prevalence, epidemiologic and clinical features. Gastroenterology research and practice 2013.
9. Alkhamiss AS (2020) Evaluation of Better Staining Method among Hematoxylin and Eosin, Giemsa and Periodic Acid Schiff-Alcian Blue for the Detection of Helicobacter pylori in Gastric Biopsies. The Malaysian Journal of Medical Sciences: MJMS 27: 53.